

# FIRST REPORT OF *MADURELLA MYCETOMI* ISOLATE THAT INDUCED SYSTEMIC PULMONARY AND MYOCARDIUM MYCOSIS WITH VERMINIOUS ENTERITIS IN *DUGONG DUGON*, OF MERSING, JOHORE

NORINA.L<sup>1\*</sup>, AIDA M.<sup>1</sup>, ZAIDIN A.<sup>1</sup>, SYED ABDULLAH S.A.K.<sup>2</sup>, TAMIMI M.A.A.<sup>2</sup>, SAROL K.<sup>3</sup>, HANAFI H.<sup>3</sup>, NOORDIN M.M.<sup>4</sup> AND MAZLINA M.<sup>4</sup>

1 Department of Veterinary Services State of Johor, Aras 4, Bangunan Dato' Mohamad Ibrahim Munsyi 79630 Kota Iskandar, Nusajaya, Johor

2 Fishery Research Institute (FRI) Rantau Abang, Turtle and Marine Endangered Species (TUMEC) Research, Jabatan Perikanan Malaysia, 23050 Dungun Terengganu

3 Regional Veterinary Laboratory Johor Bahru, 2Department of Veterinary Services, Lot PTB 11098, Jalan Taruka, Off Jalan Datin Halimah, 80350 Johor Bahru, Malaysia.

4 Faculty of Veterinary Medicine, University Putra Malaysia, Serdang, Selangor, Malaysia

\* Corresponding author: norina@dvs.gov.my

**ABSTRACT.** The major causes of the decline of the Dugong population along the urban coast of Mersing, Johor includes gill netting, subsistence hunting, habitat loss from extreme weather events that are likely to be exacerbated by climate change, human settlement, breach of the bots and sea water pollution. In March 2017, a male *Dugong dugon*, estimated age of 10 to 20 years, was incidentally found dead near Pulau Tinggi, Mersing, Johor by a fisherman. The entire body was found to have old and new scars at the anterior part of the abdomen. The right eye was protruded out and bleeding which indicated that the eye was pierced by a sharp object. Necropsy revealed the upper small intestine and the stomach compartments were semi-impacted with a massive helminth burden (more than 1,000 nematodes). *Paradujardinia halicoris* worms were identified based on morphological characteristics. Zoonotic fungus named *Madurella mycetomi* were isolated from heart and lung after incubation for 14 days. Histologically, the lung was confirmed to

have the presence of big mast cells which formed capsules, indicating presence of fungal spores causing systemic mycoses where the macrophages invade and engulf the spores. The shrinkage of myocardium myocyte and myocardium necrosis with mild vasculitis indicates heart failure. Groucott's stain confirmed *Madurella mycetomi* infection that induced systemic pulmonary and myocardium mycosis in *Dugong dugon*.

*Keywords:* *Dugong dugon*, *Paradujardinia halicoris*, *Madurella mycetomi*, zoonotic, Mersing, Johor

## INTRODUCTION

Dugongs, also known as sea cows, were considered rare in Malaysia until a dugong stranding incident was reported in Johor, Peninsular Malaysia, in 1999 which generated significant media and public interest (Marsh *et al.*, 2002; Rajamani *et al.*, 2006). This incident created the awareness on the status of the dugong in Malaysia which led to renewed interest in conducting

research on Dugong, especially with respect to post-mortem and disease findings from stranded dugongs. Dugongs can be found in the shallow waters of shoals, reefs, sand flats, and seagrass beds throughout Johor, Sabah and Sarawak. The Islands of Mersing – Pulau Tinggi, Pulau Besar and Pulau Sibul with lush vegetation, golden beaches and rich underwater flora and fauna. Their crystal clear waters are known to house the only habitat for the endangered dugong. Mersing waters, Tanjung Leman and the eastern islands off Mersing (Pulau Tinggi, Pulau Besar and Pulau Sibul) showed that Pulau Sibul and Pulau Tinggi have the highest concentration of Dugong. According to statistics provided by the Department of Fisheries Malaysia, the dugong population in waters off Johor was estimated at 50 heads, while Sabah and Sarawak have about 50. The population of dugong in Malaysia is threatened with extinction, taking into account the average death rate every year of between three to five per year.

In Malaysia, along its 4,800 km coastline, stretching along the Malay Peninsula, Sabah and Sarawak, which consists of the southern part of the South China Sea, are environments with coastal habitats — mangroves, coral reefs and seagrasses. There are 78 seagrass beds scattered throughout the Peninsular and East Malaysia. *Dugong dugon* (status: vulnerable) and *Chelonia mydas* (green turtle, status: endangered) are found to be associated and both species feed on seagrasses. Dugongs became rare because they were hunted for meat and hide (Holttum, 1954). Presently, dugongs are found in areas with abundant seagrasses such as Pulau Sibul, Pulau Tengah, Pulau Besar and Pulau Tinggi on the east coast and around Tanjung Adang-Merambong shoals of Sungai Pulai, Johore (Japar Sidik and Muta Harah, 2002). Seagrass species with low fibre and high nitrogen, and are easy to digest, seem to be the favourite food of dugongs. Two species of seaweed favoured are *Halophila ovalis* (Figure 1) and *Halodule uninervis* (Figure 2).



**Figure 1.** *Halophila ovalis* (rumpul dayung)



**Figure 2.** *Halodule uninervis*

However, the ecosystem for seaweed located along the beach, which is shallow and protected, face pollution and destruction as a result of reclamation, rapid development and trawling, thus, a risk to the survival of dugong. Many studies showing a decrease in population of dugongs in an area, can be attributed to damage of habitat especially seaweed depletion. In addition, dugongs are also at risk of being trapped in fishing equipment like drift nets used by fisherman, breach of the boats and sea water pollution.

Mycetoma has a worldwide distribution but is restricted to specific climate zones. Mycetomas are chronic, granulomatous, subcutaneous infections caused by either eumycetes fungi or actinomycetes bacteria, giving rise to eumycetomas and actinomycetomas, respectively. The disease is endemic in many tropical countries, and is characterised by slow progression with risks of bone and visceral involvement. The organisms are present in the soil, plant material, polluted aquatic environments, salt water and air (Ahmed *et al.*, 2004) and may enter the subcutaneous tissue by traumatic inoculation or by a thorn prick (Ahmed *et al.*, 2004) or other lesions of the skin. The microorganisms can be identified by fungal culture using media such as Sabourad's agar, Brain Heart Infusion agar and Malt extract agar (Ahmed *et al.*, 2004). Tropical eumycetoma is frequently caused by the fungus *Madurella mycetomatis*. There are at least two dozen species of fungi-causing eumycetoma throughout the world, but the most prevalent causative specie (approximately 70% of reported cases) is *Madurella mycetomatis*, which is associated

with black-grain mycetomas (Cortez K.J. *et al.*, 2008; Ahmed A. *et al.*, 2002).

Thus, the aim of the study was to report the findings of *Madurella mycetomatis* infection which infected the myocardium and systemic pulmonary tissues of *Dugong dugon* and its zoonotic implications. In carrying out this investigation, the common infections found in wild dugong is elucidated adding to current information on the causes of death in the dugong community which will eventually help to conserve the dugong population by effective mitigation.

## MATERIALS AND METHOD

In April 2017 at 5.30pm, a male *Dugong dugon*, estimated to be between 10 to 20 years of age, 1.3 m length, and weighing 150 kg, was found dead near Pulau Tinggi, Mersing, Johor by a fisherman. The *Dugong dugon* was declared as an endangered species by the International Union for Conservation of Nature (IUCN) (2010). The carcass was brought to the jetty of the Fisheries Development Authority of Malaysia (Lembaga Kemajuan Ikan Malaysia, LKIM), and the cosmetic necropsy was done *in-situ*. Cosmetic post-mortem was done, whereby the internal organs such as liver, lung, spleen, heart, stomach and intestine were removed but the outer body parts were maintained. A cosmetic post-mortem allows full access to all tissues required by the pathologist, but does not take significantly more time to carry out and allows for the preservation of skin and skeleton for museum based studies or preservation for artistic purposes. The internal cavity of the carcass was cleaned with water and 10 rolls of cotton were

placed in the thorax and abdominal region and the incision was sewed up using catgut strings sized 4/0. Approximately 1,500 ml of 10% formalin were injected in-between the stitches until it reached the cotton for fixation. Then, the carcass was brought back to the Fishery Research Institute (FRI) in Rantau Abang, Terengganu for further fixation. Examination of lesion on fresh lung, liver, and heart were done and samples were taken and sent for bacteriology and fungus isolation; and also were fixed in 10% buffered formalin for histopathology study. They were processed according to routine laboratory procedures. A large quantity of nematode worms were found in the stomach and anterior part of its duodenum and jejunum of the intestine. The worms were preserved uncompressed in 70% GL ethanol and were sent for parasite identification. All the samples were transported to the Regional Veterinary Laboratory, Johor Baharu, for further examination.

## RESULTS AND DISCUSSION

### Details of results from the investigation are shown as in figures below

#### ***Necropsy finding***

In general, the carcass was in good condition. Gross observation showed that entire body had presence of old scars at the anterior part of the abdomen and also the presence of ocular and oral bleeding (Figure 3 and Figure 4). A new cut was found on the left abdomen and around the mouth region. The right eye protruded out and bleeding around the eye region was noted,

which indicated that the eye was pierced by a sharp object (Figure 5). Upon observation of the thoracic and abdominal cavity filled with serous fluid. The animal had a large amount of brown, serosanguinous fluid and a moderate amount of fibrin in its peritoneal cavity. There were multifocal paintbrush and ecchymotic haemorrhages on the visceral and parietal pleura. The skeletal musculature was oedematous. All internal organs were congested while spleen and kidney were autolysed. Congested trachea, severe pulmonary congestion and hepatic congestion were observed. The dugong's upper small intestine and the stomach compartments were semi-impacted with a massive helminth burden (more than 1,000 nematodes) (Figure 6). Cause of death was not determined but was possibly associated with the parasite burden of *Paradujardinia halicoris*.

#### ***Laboratory Finding***

##### *Parasitology*

*Paradujardinia halicoris* worms were identified using stereomicroscope to differentiate between the male and female. The worm has three lips with interlabia, intestinal caecum and ventriculus (Figure 7 and Figure 8). The male worm showed presence of two spicules alae in the middle shaft (Figure 10) while the female showed presence of vulva (Figure 9).

##### *Bacteriology and Fungus*

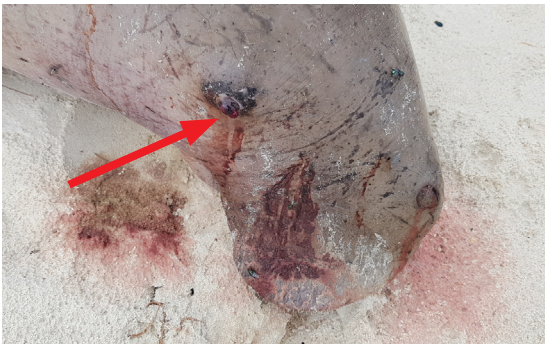*Pasteurella haemolytica var ureae* was isolated from lung, liver and spleen, *Bordetella*



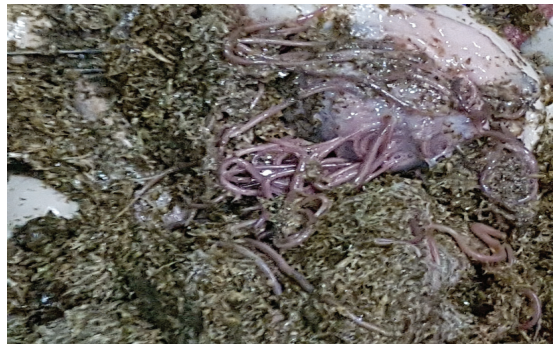
**Figure 3.** Carcass with the presence of ocular and oral bleeding.



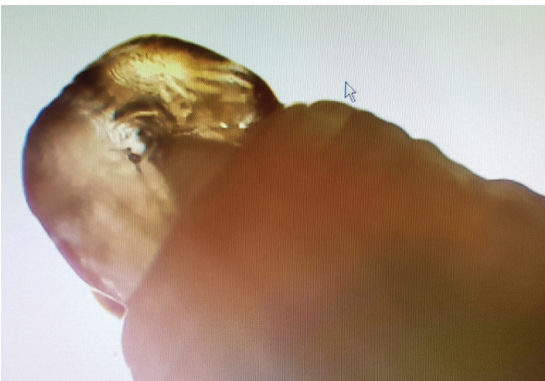**Figure 4.** Presence of old and new cuts on the left abdomen.




**Figure 5.** Protruding right eye and bleeding around the eye region suspected of being pierced by a sharp object and noted presence of cut around mouth region.



**Figure 6.** Presence of high burden of nematodes in the stomach and intestine.



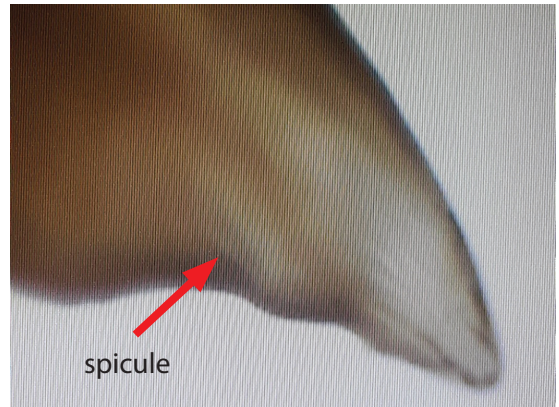
**Figure 7.** The anterior part of *Paradujardinia halicoris*.



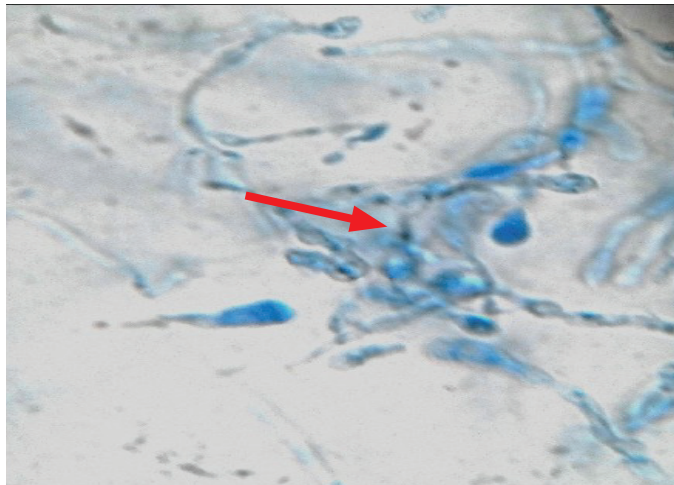
**Figure 8.** The mouth part of *Paradujardinia halicoris* with presence of three lips, interlabia, intestinal caecum and ventriculus.



**Figure 9.** Posterior end of *Paradjardinia halicoris* showing vulva region indicating female worm.



**Figure 10.** Posterior end of *Paradjardinia halicoris* showing spicule region indicating male worm.



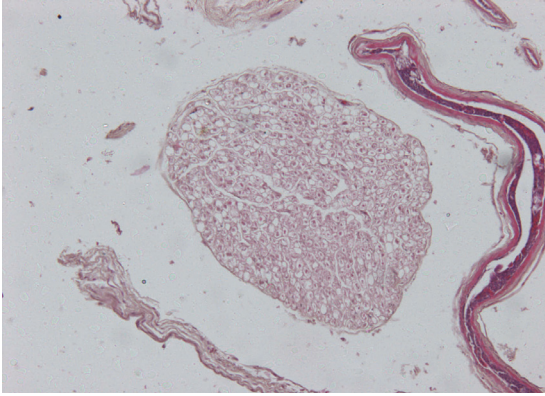
**Figure 11.** Wet mount from culture stained with lactophenol cotton blue (LCB) ( $\times 10$  magnification) showing brown pigmented septate hyphae with intercalary chlamydospores (arrow) characteristic of *Madurella mycetomi*.

*bronchiseptica* from lung and *Madurella mycetomi* fungus from heart and lung. The culture of discharged granules from heart and lung in Sabouraud's dextrose agar (SDA) grew *Madurella mycetomi* after incubation for 14 days. Confirmation the SDA culture by Wet mount stained with Lactophenol Cotton Blue (Figure 11) with presence of brown

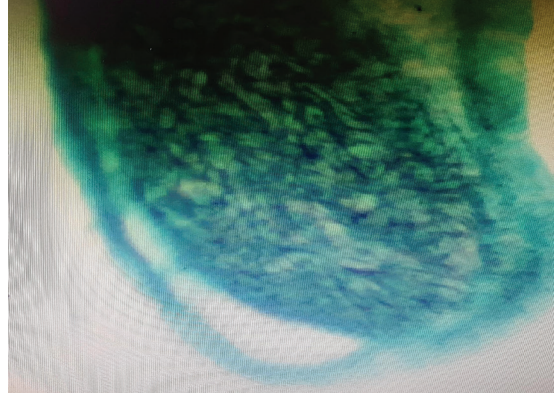
pigmented septate hyphae with intercalary chlamydospores characteristic of *Madurella mycetomi*

#### Histology

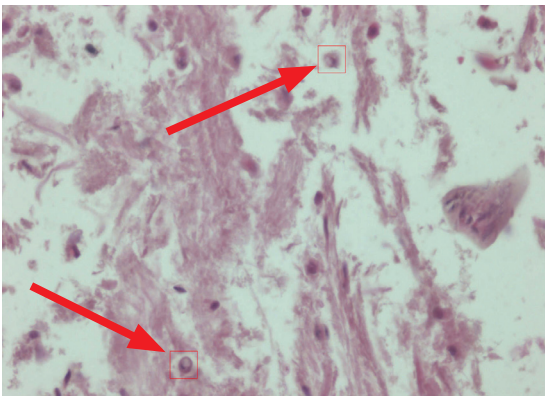
Microscopic examination on lung tissue revealed fibrous tissues and inflammation



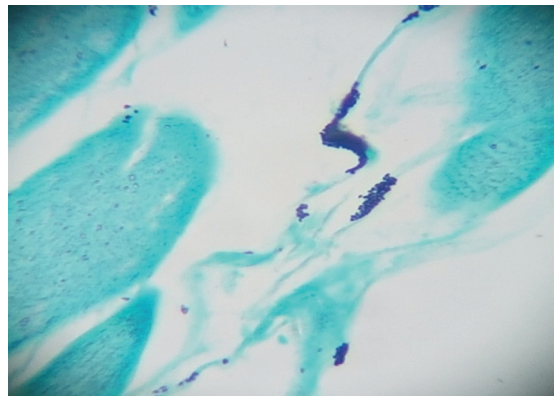
**Figure 12.** Mast cell with surrounding cartilage indicating fungus (systematic mycotic) [HE×10].



**Figure 13.** Fig.13: Pulmonary mycosis with presence of black spores indicating fungal infection [Grocott's stain ×20].



**Figure 14.** Macrophage engulfing fungal spores in the lung [×40 HE].



**Figure 15.** Myocardium with black spores indicating fungal infection [Grocott's stain ×20]

in bronchioles. Presence of big mast cells which form capsules, indicate presence fungal spores which cause systemic mycoses (Figure 12 and Figure 13). Blood vessels were surrounded by inflammatory cells which line the vessel but no evidence of vasculitis. Some macrophages are seen to invade and engulf the spores (Figure 14). Presence of mild vasculitis and necrosis was also noted which indicates heart failure. Furthermore, the case was attended to more than 24 hours after discovering the dugong,

which may have caused some loss in detail in tissues due to autolysis. The shrinkage of myocardium myocyte a mild degree of myocardium necrosis was also seen. Myocardium mycosis was present with black spores fungal infection after staining with Grocott's (Figure 15). Hepatic infiltration of neutrophils and inflammatory cells between sinusoids was observed. Piknotic nucleus and hepatocytes became disarrangement and some area of hepatocytes were seen

to be hollow or empty which indicates autolysis.

## CONCLUSION

The dugong habitat did not fall within the protected zones of the Johor state marine parks and the Sultan Iskandar Marine Park (TLSI). According to the research by MareCet since 2010, the female dugong and their calves in the Pulau Sibut-Tinggi area are all outside the protected zone. Johor has 13 marine parks, including the Pulau Besar, Pulau Tinggi and Pulau Sibut Marine Parks (Anon, 2010). The TLSI which was opened in July 2017, is operated by the Johor National Parks Corporation. TLSI covers a zone of up to three nautical miles as it is the norm with other marine parks. Fishing and all kinds of activities that damage the marine biological ecosystem are prohibited at all the marine parks concerned. The survey also showed that Johor's dugong and sea grass habitats were situated outside the protected zones of its marine parks, thus the state authorities have decided to establish a sanctuary to protect their natural terrain.

As seagrass is the main source of nourishment for dugong, protecting the underwater seagrass beds is of paramount importance to ensure the continued survival of these creatures. Seagrass ecosystems are very sensitive and are readily destroyed by anything that increases turbidity and deprives them of light or causes nutrient enrichment and increased epiphytic growth. Dugongs' dependence on seagrasses mostly restricts them to shallow, nearshore waters, habitats that are increasingly being occupied by humans and influenced by human

activities. It is likely that human activities have contributed to the substantial decline in dugong numbers along the urban coast of Mersing especially in the Pulau Sibut-Tinggi area. Human activities, such as trawling and dredging and water pollution, have a negative effect on sea-grass ecosystems, as have natural events, such as cyclones and flooding (Heinsohn and Spain, 1974; Marsh et al., 2000; Greenland and Limpus, 2007). Several dugong mortalities each year occur because of boat strikes and netting which is in agreement with previously published data (Greenland and Limpus, 2007), human activities were identified as a significant cause of dugong mortality.

Little is known about Dugong's common disease processes and causes of natural mortality. The carcass was found to have a massive helminth (*Paradujardina halicoris*) burden in its stomach. Little is known about the pathogenicity of helminth parasites in sirenians (Bossart, 2001), and *Paradujardina halicoris* were often found in large numbers in dugong stomachs, including those in apparently good body condition. The burden of worms may have caused physical effects on gastric function, or less likely, perhaps, parasite-induced appetite suppression, similar to that which occurs with some intestinal parasites in domesticated animals (Dynes et al., 1998). Eumycetoma is a subcutaneous fungal infection in which the etiological agent occurs in the form of more or less compact mycelial grains. Tropical eumycetoma is frequently caused by the fungus *Madurella mycetomatis*. The disease is characterised by extensive subcutaneous masses, usually with sinuses draining pus, blood, and



fungal grains. *Madurella mycetomi* (black grain mycetoma) is the most common eumycetoma and worldwide, followed by *Scedosporium apiosperma*, *Scedosporium prolificans*, and *Madurella grisea* (McGinnis and Fader, 1988). It is a slow growing fungal infection, which initially involves the skin and subcutaneous tissues and progresses to involve deeper structures. Upon examination it was found that the surface of the carcass was present with the old and new scars indicating that the dugong was injured previously with sharp objects, without any wound treatment. A possible pathogenesis may include direct introduction of an infectious agent through a penetrating wound or the hematogenous spread of infection from some other focus. The wound progressively healed naturally probably by being traumatically inoculated with plant materials or soil contaminated by these fungi. The infection is classically characterized by the presence of subcutaneous nodules, increasing in size, which may suppurate and drain a serous, serosanguineous or purulent discharge through multiple sinus tracts (Ahmed *et al.*, 2004). Although the disease incubation time remains unclear, symptoms may appear several months to years' post infection (Ahmed *et al.*, 2004). Microscopically, the lung revealed fibrous tissues and inflammation in bronchioles. There was also presence of big mast cells which formed capsules, indicating presence of fungal spores causing systemic mycoses where the macrophages invade and engulf the spores. Presence of mild vasculitis and no bend necrosis indicates the heart failure was evident. The shrinkage of myocardium myocytes and presence of mild degree of

myocardium necrosis with black spores indicate fungal infection after staining with Groucott's.

Unfortunately, there has been no previous reported case of *Madurella mycetomatis* in marine animal especially in *Dugong dugon*. This is the first case of *Madurella mycetomatis* infection which leads to systemic pulmonary and myocardium mycosis with verminous *Paradujardinia halicoris* infestation in Dugong.

In conclusion, the post-mortem found possible diseases that could infest wild dugong and it gives an indication in future for pathologists and veterinarians on what to look for in cases of dead dugongs. The findings of fungal and parasitic infestations are important and significant findings in future conservation work that needs to be carried out. These efforts will help to maintain the dugong population in the coastal waters of Malaysia.

## REFERENCES

1. Ahmed A., Adelmann D. and Fahal A., Verbrugh H., van Belkum A. and de Hoog S. (2002). Environmental occurrence of *Madurella mycetomatis*, the major agent of human eumycetoma in Sudan, *J Clin Microbiol*, **40(3)**: 1031-1036.
2. Ahmed A.O., van Leeuwen W. and Fahal A., van de Sande W., Verbrugh H. and van Belkum A. (2004). Mycetoma caused by *Madurella mycetomatis*: a neglected infectious burden, *Lancet Infect Dis*, **4(9)**: 566-574.
3. Anonymous (2010). *Sanctuary plans for sea cows in Johor*. In: PressReader-The Borneo Post (Sabah). <https://www.pressreader.com/malaysia/.../281818578623653>. Accessed 7 Mar 2017
4. Bossart G. (2001). Manatees. In: *CRC Handbook of Marine Mammal Medicine*. 2nd Edition, Dierauf L. and Gulland F. (eds.). CRC Press LLC, Boca Raton, Florida, pp. 939-960.
5. Cortez K.J., Roilides E. and Quiroz-Telles F. *et al.* (2008). Infections cause by *Scedosporium* spp, *ClinMicrobiol Rev*, **21(1)**: 157-197.

6. Dynes R., Poppi D., Barrell G. and Sykes A. (1998). Elevation of feed intake in parasite-infected lambs by central administration of a cholecystokinin receptor antagonist. *British Journal of Nutrition*, **79**: 47-54.
7. Greenland J. and Limpus C. (2007). I: Dugong In: *Marine wildlife stranding and mortality database annual report 2007*, Queensland Environmental Protection Agency Conservation technical and data report, Brisbane, Queensland, Australia, 23 pp.
8. Heinsohn G. and Spain A. (1974). Effects of a tropical cyclone on littoral and sub-littoral biotic communities and on a population of dugongs (*Dugong dugon* (Müller)). *Biological Conservation* **6**: 143-152.
9. Holttum R.E. (1954). *Plant life in Malaya*. Longman, London.
10. International Union For Conservation Of Nature (IUCN) (2010). *IUCN Red List of Threatened Species*. Version 2010.2. [www.iucnredlist.org](http://www.iucnredlist.org). Accessed July 2010.
11. Japar Sidik Bujang, Muta Harah Zakaria (2002). Seagrasses in Malaysia. In: *World Atlas of Seagrasses*. Green E.P., Short F.T., Spalding M.D. (eds.), California University Press. Chapter 14, pp 166-176.
12. Marsh H., Penrose H., Eros C., Hughes J. (2002). Dugong status reports and action plans for countries and territories. *UNEP early warning and assessment report series*. IUCN Publication. 162 pp.
13. Marsh H., Eros C., and Webb R. (2000). Dugongs in health and disease. In: *Proceedings 335, Proceedings (University of Sydney Postgraduate Foundation in Veterinary Science, Marine Wildlife: The Fabian Fay Course of Veterinarians*, Sydney, Australia, pp. 301-317
14. McGinnis M.R., Fader R.C. (1988). Mycetoma: a contemporary concept. *Infect Dis Clin North Am.* **2**: 939-954.
15. Rajamani L., Cabanban A.S., Ridzwan A.R. (2006). Indigenous use and trade of dugong (*Dugong dugon*) in Sabah, Malaysia. *Ambio* **35**: 266-268.

---

**ACKNOWLEDGMENTS.** We acknowledge pathologists, veterinarians, and staffs from Fishery Research Institute Dungun, Terengganu, staffs from Regional Veterinary Laboratory Johor Baharu and those who involved directly and indirectly in performed or assisted with the post-mortem examinations.